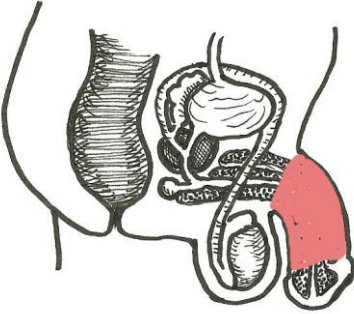
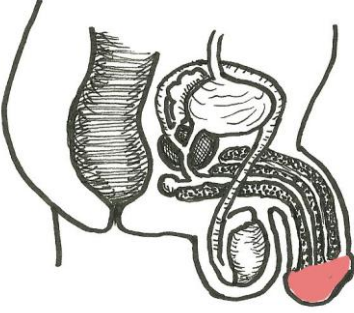
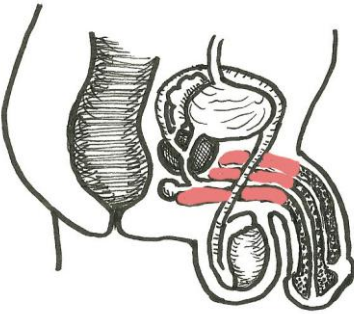
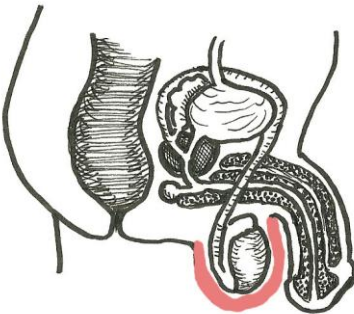
	<p><b>ORIENTATION TO THE MALE PELVIS</b></p> <p>If you dissected the male body in such a way as to cut the body into a right and left half exactly down the middle you would get the following view of the insides as you looked at the cut surface.</p>
	<p><b>THE SHAFT OF THE PENIS</b></p> <p>The part of the penis shaped like a cylinder.</p>
	<p><b>THE GLANS (THE HEAD) OF THE PENIS</b></p> <p>The rounded portion at the end of the penis.</p>
	<p><b>THE ROOT OF THE PENIS</b></p> <p>The deepest part of the penis. It is not visible from the outside.</p>
	<p><b>THE SCROTUM</b></p> <p>The pouch of skin that allows the testicles to hang away from the heat of the body.</p>