
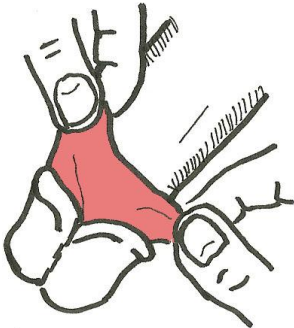
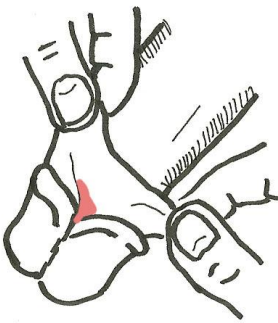
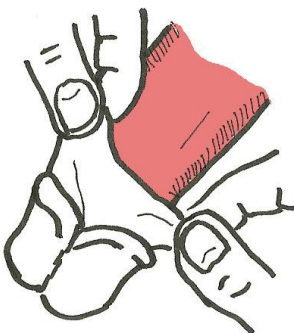
	<p><b>THE GLANS</b></p> <p>The structure at the end of the penis furthest from it's attachment to the body is the glans.</p>
	<p><b>THE CORONA</b></p> <p>This is the ridge that runs all the way around the base of the glans.</p> <p>The corona has many sensory receptors.</p> <p>Some men have little pearly papules on the corona. There is no health concern if they do, it is a normal variant.</p>
	<p><b>THE FORESKIN OR PREPUCE</b></p> <p>This is some loose skin that usually covers the glans of the penis when the penis is flaccid (at rest). When the penis becomes erect the glans will be uncovered as the loose foreskin is retracted along the longer shaft.</p> <p>Many men no longer have a foreskin because it was removed by a procedure called male circumcision.</p>
	<p><b>THE FRENULUM</b></p> <p>The frenulum is the portion of the foreskin that connects the foreskin with the central area along the edge of the glans on the underside of the penis.</p> <p>The frenulum has many sensory receptors</p>
	<p><b>THE SHAFT</b></p> <p>The central region of the penis.</p> <p>The part of the penis that is shaped like a cylinder.</p>