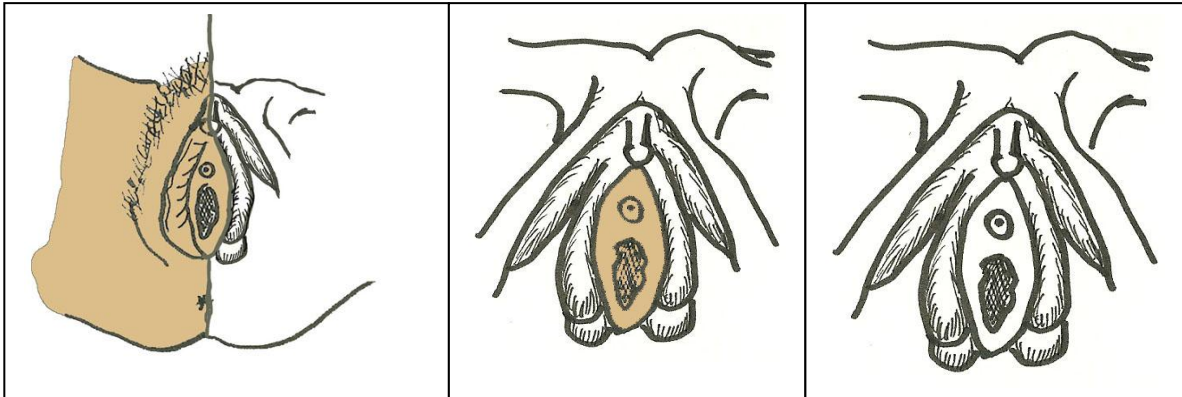

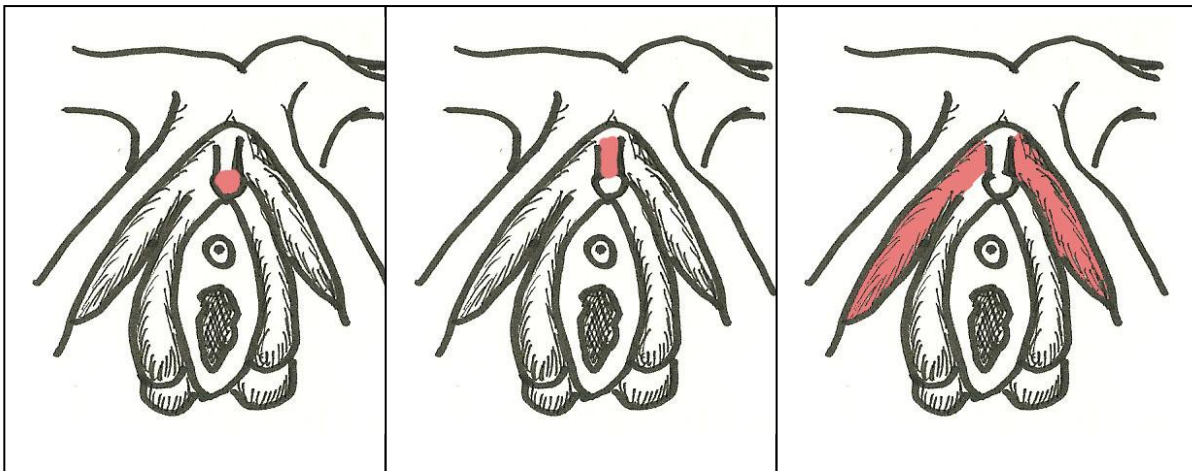
This is a series of three pictures to try to orient you to what the drawings represent.

PICTURE #1 - on the left side of the picture the vulva is intact (nothing has been cut away)

PICTURE #1 – on the right side of the picture the skin and fat have been removed to reveal the deeper structures.

PICTURE #2 – the vestibule with the urethra and introitus are intact – but everywhere around the vestibule the skin and fat have been removed to show only the deeper structures

PICTURE #3 – The same as picture number 2, but no color shading has been used to distinguish surface structures (the vestibular area without anything removed) from deeper structures (only visible once overlaying skin and fat have been removed).



This is a series of pictures to show the regions of the clitoris.

PICTURE #1 – the head of the clitoris – also known as the GLANS

PICTURE #2 – the SHAFT of the clitoris

PICTURE #3 – the roots of the clitoris – also known as the CRURA